

# We are IntechOpen, the world's leading publisher of Open Access books Built by scientists, for scientists

3,500

Open access books available

108,000

International authors and editors

1.7 M

Downloads

Our authors are among the

151

Countries delivered to

TOP 1%

most cited scientists

12.2%

Contributors from top 500 universities



WEB OF SCIENCE™

Selection of our books indexed in the Book Citation Index  
in Web of Science™ Core Collection (BKCI)

Interested in publishing with us?  
Contact [book.department@intechopen.com](mailto:book.department@intechopen.com)

Numbers displayed above are based on latest data collected.  
For more information visit [www.intechopen.com](http://www.intechopen.com)



---

## Ozone in Dentistry

---

Aysan Lektemur Alpan and Olcay Bakar

Additional information is available at the end of the chapter

<http://dx.doi.org/10.5772/intechopen.75829>

---

### Abstract

Ozone (triatomic oxygen or trioxxygen) is the combination of three naturally occurring oxygen atoms. Ozone therapy is an alternative to traditional approaches in dentistry. The main feature suggests that ozone can be used in dentistry as a strong antimicrobial agent. In addition, ozone has antimicrobial, immune system regulatory, metabolic rate, and biosynthesis-enhancing effects. Ozone affects cellular and humoral immunity. It has positive effects on oxygen transport in the body; production of adenosine triphosphate (ATP); and production of enzymes such as glutathione peroxidase, catalase, and superoxide dismutase. Ozone use in dentistry can be made possible via ozone gas, ozonated water, ozonized olive, or sunflower oil. Ozone is used in periodontology (gingivitis, periodontitis, periimplantitis, surgical injuries, prophylaxis), oral pathologies (stomatitis, aphthous ulceration, candidiasis, herpes infections), endodontics (root canal treatment, the fistula, abscesses), oral surgery (hemostasis, wound healing, implantation, reimplantation, tooth extraction), prosthodontics (disinfection of crowns, disinfection of the alloy part of partial dentures), orthodontics (TME function disorders, trismus, myoarthropathies), and restorative dentistry (caries, dentine hypersensitivity, cracked tooth syndrome, bleaching, disinfection of cavity). As a result of the studies performed, ozone therapy in dentistry should be considered as an aid to conventional treatments.

**Keywords:** antioxidant, antimicrobial, dentistry, immunostimulating, ozone

---

### 1. Introduction

Ozone (triatomic oxygen or trioxxygen) is the combination of three naturally occurring oxygen atoms. Ozone is present in the gas form in the concentration of 1–10 ppm in the stratosphere in nature. Molecular weight is 47.98 g/mol, and it is highly endothermic and also thermodynamically unstable as an oxygen compound. Depending on environmental

conditions, such as short half-life, pressure, and heat, molecular oxygen in ozone can be converted to atomic oxygen in a short time [1]. Ozone is the third most powerful oxidant known that does not possess radical properties due to its chemical structure [2]. Ozone has a higher energy than atmospheric oxygen, 1.6 times more dense, and 10 times more soluble in water than oxygen [1]. In 1785, Van Marum noticed that when the spark occurred in the electrostatic machine, there was a peculiar smell of air around him. In 1801, Cruickshank heard the same smell on the anode side during electrolysis of water. Sconbein described this substance in 1840 as "Ozein," meaning to smell it in Greek. In 1856, Werner Von Siemens designed an ozone generator in 1857, which was used in the disinfection of operating theaters. Since these types of generators are the forerunners of later generations, these types of generators in the market are called "Siemens type" ozone generators. In 1860, the first ozone generator in Monaco was used for plant treatment. In 1870, for the first time in medical treatment, it was used by Lender [3].

In the nineteenth century, Dr. Fisch used ozonated water in his practice for the first time in dentistry and introduced it to Dr. Erwin Payr who was a German surgeon. Dr. Erwin Payr used ozone in surgery and he reported a publication (of 290 pages) entitled "Ozone Treatment in Surgery" (*Über Ozonbehandlung in der Chirurgie*) at the 59th Meeting of the German Surgical Society in 1935 [4].

As modern science is used in the practice of dentistry, it is also changing and developing with time. Ozone therapy is an alternative to traditional approaches and can be considered as a model to help in healing. Emerging technology has led us to less invasive and more conservative work.

The main feature suggests that ozone can be used in dentistry as a strong antimicrobial agent. It is effective against Gram (+, -) bacteria, viruses, and fungi. Ozone, which is used in dental prosthesis, endodontics, restorative dentistry, periodontology, and oral and maxillofacial surgery, offers great advantages in addition to traditional treatments [5, 6].

Ozone shows the antimicrobial effect by creating cell membrane damage. It reacts with the double bonds of the hydrocarbons in the cell membrane and causes the modification of the cell content by the action of the secondary oxidant. Ozone is highly effective against antibiotic-resistant species. The antimicrobial activity of ozone is increased in liquid and acidic pH [6]. The basis of the ozone action mechanism in viral infections is inhibiting infected cell peroxide sensitivity and the synthesis of viral proteins by altering the activity of the reverse transcriptase enzyme [7].

Ozone affects cellular and humoral immunity. It stimulates the proliferation and immunoglobulin synthesis in immune cells, accelerates the sensitivity of macrophage phagocytosis, and activates other macrophage functions. This activation results in the production of specific molecules called cytokines. This suggests that ozone administration at low doses is beneficial to people with an impaired immune system. Ozone also promotes the synthesis of biologically active molecules such as interleukins, leukotrienes, and prostoglandins, thereby helping to reduce inflammation and improve wound healing [6, 8].

Ozone increases the partial oxygen pressure in the tissues and increases the oxygen transport in the body causing changes in cell metabolism. This change increases the use of oxygenated respiration and therefore energy sources (glycolysis, cycling of the Krebs,  $\beta$ -oxidation of fatty acids). It also prevents the erythrocytes from collapsing and increases the contact surface of erythrocytes for oxygen transport. It activates the Krebs cycle, which stimulates adenosine triphosphate (ATP) production, and causes a significant reduction in nicotinamide adenine dinucleotide (NADH) leading to oxidation of cytochrome C. Ozone therapy stimulates production of enzymes such as glutathione peroxidase, catalase, and superoxide dismutase which act as free radical scavengers [9].

It promotes intracellular protein synthesis by stimulating mitochondria and ribosomes. This alteration may lead to activation of cell functions and regeneration potential of tissues and organs. Ozone causes dilation in arterioles and venules by stimulating the release of vasodilators such as nitric oxide [6, 10].

### **1.1. Dental treatment modalities of ozone therapy**

- Biofilm purging (elimination of bacterial pathogens) [5].
- Periodontal pocket disinfection and osseous disinfection.
- Prevention of dental caries.
- Endodontic treatment.
- Tooth extraction.
- Tooth sensitivity.
- Temporomandibular joint treatment.
- Gingival recession (exposed root surfaces).
- Pain control.
- Infection control.
- Accelerating of wound healing.
- Tissue regeneration.
- Controlling halitosis.
- Remineralization of tooth surface.
- Teeth whitening (bleaching).

Ozone use in dentistry can be possible via ozone gas, ozonated water, ozonized olive, or sunflower oil [2]. Ozone, a very unstable molecule in gas form, lasts a few minutes in the air, while

the aquatic life lasts a few days. However, it has been reported that ozone can be measured for months and years when dissolved in an oil-based content such as 100% pure olive oil [11].

## 1.2. Ozone toxicity

It should not be forgotten that ozone is a toxic gas if it is inhaled. Eyes and lungs are very susceptible to ozone. For this reason, long-term exposure to ozone results in some side effects, such as epiphora, irritation of the upper airways, bronchoconstriction, rhinitis, cough, headache, and vomiting may occur, depending on the time of the ozone exposure. In such cases, it has been reported that administering supportive treatment such as oxygen, ascorbic acid, vitamin E, and N-acetylcysteine to the patient would be beneficial [12–14]. Pathological and anatomical studies showed that blood clotting is impaired in a typical table ozone poisoning and has been shown to occur in lung hematomas. However, the ozone gas is not a chemical disinfectant, and after completing the disinfection task due to its unstable structure, it rapidly transforms into oxygen [2].

As ozone therapy is an atraumatic treatment method, the areas of use in dentistry are increasing with the protection of healthy and decayed dental caries, disinfection of dental unit water systems, antibacterial effect in avulse teeth, and healing properties of oral lesions.

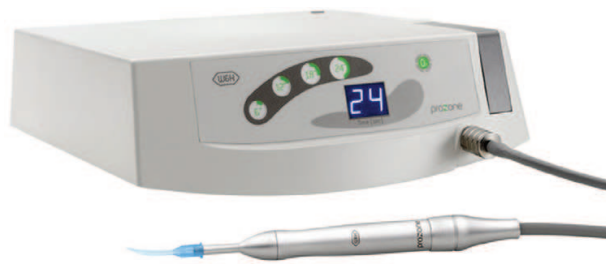## 1.3. Contraindications of ozone therapy

- Pregnancy [7].
- Hyperthyroidism.
- Glucose-6-phosphate-dehydrogenase deficiency.
- Severe anemia.
- Severe myasthenia.
- Active hemorrhage.
- Acute alcohol intoxication.

Ozone can be used for prophylaxis in dentistry due to its biological properties and for the treatment of various diseases. Ozone is used in periodontology (gingivitis, periodontitis, peri-implantitis, surgical injuries, prophylaxis), oral pathologies (stomatitis, aphthous ulceration, candidiasis, herpes infections), endodontics (root canal treatment, the fistula, abscesses), surgical procedures (hemostasis, wound healing, implantation, reimplantation, tooth extraction), prosthodontics (disinfection of crowns, disinfection of the alloy part of partial dentures), orthodontics (TME function disorders, trismus, myoarthropathies), and restorative dentistry (caries, dentine hypersensitivity, cracked tooth syndrome, bleaching, disinfection of cavity) [15].

## 1.4. Ozone gas generating systems

1. Corona discharge ozone generators: with the corona discharge method, ozone gas ( $O_3$ ) is formed by breaking the double bond of the oxygen molecule ( $O_2$ ) by passing electric current and combining the other free oxygen atom [6].



**Figure 1.** An ozone-generating system used in dental practice [17].

2. Ultraviolet ozone generators: the ultraviolet method is used to break up the oxygen molecule by passing it through an ultraviolet bulb which emits light with a wavelength shorter than 220 nm, and the released oxygen atom combines with the other oxygen molecule to form the ozone gas.
3. Cold plasma system: it is used for purification of air and water.

Thanks to innovative technology, ozone has become painless, safe, effective, and easy to apply in many areas of medicine. New-generation medical ozone generators can produce ozone at very narrow therapeutic ranges (0.1–2.1  $\mu\text{g/s}$ ) from oxygen molecules present in the atmosphere or in liquids. The applied microcurrent (max 100  $\mu\text{A}$ ) is completely harmless to both the patient and the implementer [16] (**Figure 1**).

## 2. Role of ozone on restorative dentistry

In recent years, ozone treatment has begun to be used as a new method in the treatment of caries. It has been suggested that application of ozone to caries stops or hardens these lesions. Application of ozone to caries will provide an alternative to conventional treatment modalities. It was demonstrated in studies that ozone can be used to eradicate bacteria in carious lesions, painlessly.

Baysan et al. [18], found a significant decrease in *Streptococcus mutans* and *Streptococcus sobrinus* numbers on primary root carious lesions which were applied ozone gas for a period of 10 s. Then, the in vitro study was adapted to a randomized clinical trial and the results of the controls were measured by using DIAGNOdent and ECM. A significant increase in remineralization was observed in ozone groups. In a randomized trial, Holmes evaluated the effect of ozone on surface hardness (soft, brittle, stiff) on root caries. At the end of 12 months, 100% of the teeth treated with ozone treatment had hardened caries surfaces, and 37% of caries in the control group without treatment reported that the lesions were getting worse [19]. Samuel et al [20] evaluated the effect of ozonated water in remineralizing artificially created initial enamel caries using laser fluorescence and polarized light microscopy. According the results, reduced DIAGNOdent scores and greater depth of remineralization were gained following application of ozonated water and the ozone-treated group exhibited maximum remineralization under the polarized light microscopy. Polydorou et al. [21] used two different bonding systems, 40 and 80 s, in ozone-applied cavities in an in vitro study. Two different bonding systems were

performed without any application of ozone to the control group. The teeth were then restored with composite resin. *Streptococcus mutans* ratio in the ozone group for 80 s values was statistically decreased in comparison to the other groups. These results are promising for applications directed at *Streptococcus mutans*, which is the most important pathogen responsible for caries. On the other hand, in a Cochrane review, authors concluded that application of ozone on caries provides no evidence in terms of arresting or reversing the decay process [22].

Tooth structure can lessen via attrition, abrasion, erosion, trauma from occlusion, and it may cause wearing away of enamel and dentin, thereby causing hypersensitivity. Ozone application has been found to reduce sensitivity in exposed enamel and dentin and also in cases of root sensitivity. It was found that 40–60 s application of ozone offers pain reduction in sensitive teeth. Ozone initiates removal of the smear layer, opens the dentinal tubules, and widens them so that the remineralizing agents—calcium and fluoride ions—can enter the dentinal tubules easily, readily, and completely, preventing the fluid exchange from dentine tubules. Depending on this, termination of sensitivity occurs following ozone application in a short time and also lasts longer than conventional treatment modalities [9].

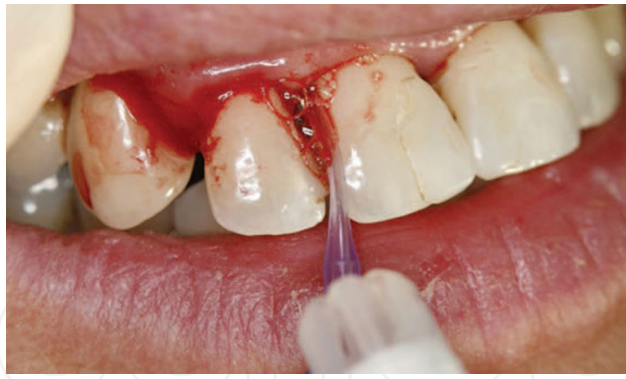Delay and Holmes [23] reported that the ozone application provides a reduction in the symptoms of patients with cracked tooth syndrome. Medozon, an ozone-generating device, claims that ozone application of 60–120 s to the cracked area in the fractured tooth syndrome provides long-lived restorative material [24].

Ozone can be used on root canal-treated discolored teeth by irradiating the root canal for 3 min. This treatment provides good esthetic result by bleaching the tooth. Tessier et al. [25] evaluated the ozone efficacy in an experimental rat model used to lighten tetracycline-stained incisors. At the end of the study, it was found that ozone application could be successfully used for lightening the yellowish tinge of tetracycline-stains incisors.

### 3. Role of ozone on periodontology

The main ozone application area in periodontology is relayed on its antimicrobial properties. It seems to be effective against both Gram (+) and Gram (–) bacteria, viruses, and fungi. It can be applied into the periodontal pocket with the different tips of generators (**Figure 2**), ozonated water, or ozonated oil.

Nagayoshi et al. [27] investigated the effect of ozonated water on cell permeability and viability of microorganisms. Gram-negative bacteria (*Porphyromonas gingivalis*, *Porphyromonas endotalis*) was found to be more sensitive to ozone than streptococci and *Candida albicans*. In addition, the ozonated water has strong bactericidal action against *Streptococcus mutans* bacteria in the plaque biofilm. Also it was reported that ozonated water inhibited the experimental bacterial plaques in vitro. In another study, it was concluded that high concentrations of ozone water (20  $\mu\text{g ml}^{-1}$ ) had an antibacterial effect equal to 0.2% concentration of chlorhexidine, whereas highly concentrated ozone gas ( $\geq 4 \text{ g m}^{-3}$ ) had an antibacterial effect of as much as 2% chlorhexidine and more effective than 0.2% chlorhexidine [28]. Ramzy et al. [29] used 150 ml of ozonized water for periodontal pocket irrigation (5–10 min once weekly, 4 weeks)



**Figure 2.** Ozone application into periodontal pocket [26].

in patients suffering from aggressive periodontitis. Statistically significant decreases in terms of pocket depth, plaque index, gingival index, and bacterial count were observed. In a study, authors compared the effect of oral irrigation with ozone water, 0.2% chlorhexidine and 10% povidone iodine, in chronic periodontitis patients and concluded that local ozone application could be used as a powerful atraumatic and antimicrobial agent in the nonsurgical treatment of periodontal disease for both home care and professional practice [30].

In contrast, Eltaş and Yavuzer applied ozone gas in addition to scaling and root planning in acute gingivitis patients. Changes in plaque index, pocket depth, and clinical attachment levels did not differ significantly between groups at 4 weeks after treatment [31]. Yılmaz et al. [32] investigated the changes in clinical and microbiological parameters of mechanical treatment, mechanical treatment + erbium: yttrium-aluminum-garnet laser, and mechanical treatment + gas ozone application in chronic periodontitis. Attachment gain and pocket depth reduction were found to be greater in the laser group than in the other groups. Although not statistically significant, the decrease in anaerobic flora was observed in both laser and ozone groups.

Karapetian et al. compared ozone therapy with surgical procedures and conventional methods in patients with periimplantitis and stated that the most effective method to eliminate bacteria was ozone therapy [33]. In an in vitro study, gaseous ozone (140 ppm, 33 mL/s) for 6 and 24 s was applied to saliva-coated titanium (SLA and polished) and zirconia (acid etched and polished) disks to determine the antibacterial effect on periimplantitis caused by bacteria such as *Streptococcus sanguinis* and *Porphyromonas gingivalis*. Gaseous ozone showed selective efficacy to reduce adherent bacteria on titanium and zirconia without affecting adhesion and proliferation of osteoblastic cells [34].

#### **4. Role in bone regeneration**

Besides the antiseptic and disinfectant properties of ozone, it was also investigated for its effects on bone regeneration in recent years. One of the first study about this subject belonged to Özdemir et al. [35]. According this study results, ozone application combined with autograft provided an increase the amount of total bone area and osteoblast count.



Kazancioglu et al. [36] compared the effects of low-dose laser therapy and ozone treatment on bone regeneration in 5-mm critical-size defects in rats, and all defects were restored with biphasic calcium phosphate grafts. According to the histomorphometric measurements, the new bone area in the ozone group was statistically higher than the control and low-dose laser group.

In another study comparing the effects of hyperbaric oxygen and systemic ozone administration, the rats were sacrificed on days 5, 15, and 30, postoperatively. There was no difference in bone formation between hyperbaric oxygen and ozone [37].

Lektemur Alpan et al. [38] used diabetic rat calvarial defects with xenograft, and they concluded that the ozone accelerated bone morphogenetic protein-2 and osteocalcin positivity followed by accelerated xenograft resorption and enhanced bone regeneration.

## 5. Role of ozone in oral surgery

Ozone therapy has a vast range of applications in oral surgery because of its biological properties such as enhancing wound healing, improving several properties of erythrocytes, and facilitating oxygen release in the tissues. All these biological events cause and hence improve the blood supply to the ischemic zones leading to use of ozone in cases of wound-healing impairments, following surgical interventions like tooth extractions or implant dentistry.

Ozone treatment can be applied in cases such as disinfection of wound area, treatment of soft tissue lesions (aphthous ulcers, herpes simplex, herpes zoster, etc.), healing disorders in bone and soft tissue, alveolitis, periimplantitis, bisphosphonate-related osteonecrosis, tooth transplantation, and decontamination of root surfaces of avulsed teeth planned to be reimplanted [39]. It is possible to apply ozonized water to infections that may occur after osteotomy in oral surgery. In some prospective studies, it has been shown clinically and histologically that ozonized water has a positive effect on soft tissue healing. In a prospective study involving 250 patients, application of ozone water as a cooling and flushing agent during third molar osteotomies has been shown to reduce infectious complications after surgery [39]. Kazancioglu et al. evaluated the effect of ozone therapy on pain, swelling, and trismus following third molar surgery, and they concluded that ozone application effectively reduced postoperative pain; however, it had no effect on swelling and trismus [40].

Ahmedi et al. [41] evaluated the efficacy of ozone gas on the reduction of dry socket, which occurred after surgical extraction of lower jaw third molars. Two groups were evaluated: in the control group, saline solution was used for irrigation of extraction sockets and, intra-alveolar ozone was applied at 12 s (Prozone, W&H, UK) in the experimental group. They concluded that the ozone gas has a positive effect on reducing the development of dry socket and pain following third molar surgery depending on metabolic capabilities of ozone for promoting hemostasis, increasing the supply of oxygen, and inhibiting bacterial proliferation.

In a study, ozone therapy was compared with the photo-biomodulation therapy in mental nerve injury by counting Schwann cells and fasciculated nerve branches and measuring fascicular nerve areas. At the end of the study, a better healing pattern was observed in the

treatment groups. The number of Schwann cells was markedly larger in the ozone treatment and photo-biomodulation groups than in the control group [42].

The effects of ozone therapy stimulating cell proliferation and soft tissue healing must be taken into account in the treatment of bone necrosis in patients using bisphosphonates [43]. Many studies have been carried out on the use of ozone in osteonecrosis cases occurring in jaws due to the use of bisphosphonates. Similar results were obtained in these clinical trials with different routes of administration of ozone (gas, ozonated water, and oil) [44–46]. After radiotherapy in maxilla or mandible, the amount of oxygen in the affected area is considerably reduced. Radiotherapy leads to obliteration of intrabony vessels and inadequate vascular support in spongiosal medullary spaces resulting in xerostomia, mucositis, or loss of taste sensation. As a result, fibrosis and aseptic osteonecrosis may occur. Recovery after surgical procedures is impaired after tooth extraction from this kind of bone in comparison to healthy bones which have adequate blood supply. Such cases are always at risk of persistent osteoradionecrosis [47].

Akdeniz et al. [48] performed a study on human primary gingival fibroblasts exposed to cytotoxic concentrations of bisphosphonates. They concluded that ozone gas plasma therapy significantly decreased the genotoxic damage and this application provided 25%, 29%, and 27% less genotoxic damage, respectively, in bisphosphonate groups and improved the wound closure rate on human gingival fibroblasts.

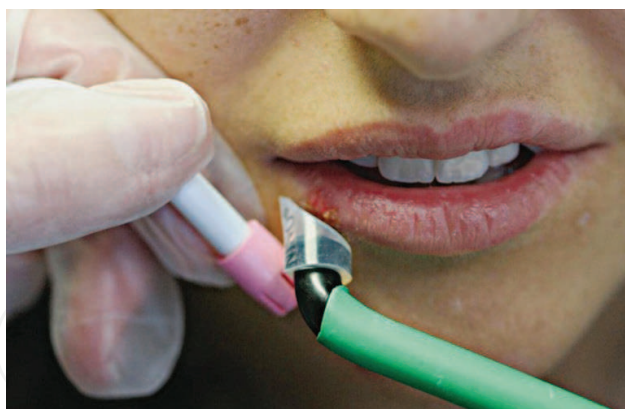
Doğan et al. [49] investigated the effects of ozone on cancer progression and survival with radiotherapy. Experimental tongue cancer was formed in rats and were separated into four groups. Ozone groups were received 1 ml at a concentration of 15 mcg/ml ozone (rectal 4 sessions, for 5 days after 22 week). Groups that received ozone showed more histopathologic improvements in comparison to other groups. Radiotherapy combined with ozone therapy has provided more survival rate and tumoral reduction than the other groups.

## 6. Role in prosthodontics

Dentures are commonly inhabited by microbial plaque, especially *Candida albicans*. Denture stomatitis is routinely encountered in clinical practice, which can be prevented by effective denture plaque control. One successful method to do so is the use of ozone as disinfecting agent to clean denture. Arita et al. [50] concluded that exposure of dentures to flowing ozonated water (2 or 4 mg/l) for 1 min can reduce the number of *Candida albicans*.

Oizumi et al. [51] compared the microbicidal effect of gaseous ozone with that of ozonated water on oral microorganisms (*Streptococcus mutans*, *Staphylococcus aureus*, *Candida albicans*). They concluded that direct exposure to gaseous ozone seems to be a more effective microbicide than ozonated water for decreasing the microorganisms.

In another study, ozonized olive oil efficacy was evaluated in the treatment of oral lesions and conditions (aphthous ulcerations, herpes labialis, oral candidiasis, oral lichen planus, and angular cheilitis) (**Figure 3**). The ozonized olive oil was applied twice. All of the conditions showed improvement in the signs and symptoms at the end of 6 months [52].



**Figure 3.** Ozone application on herpes labialis.

Temporomandibular disorder (TMD) is a pathological condition involving both the muscular and skeletal system in the temporomandibular joint region (TMJ). This is characterized by pain in the preauricular region during jaw movements, limitation during mandibular movements, pain during chewing muscles and palpation in the TMJ region, and TMJ voices. Pain usually occurs during chewing or mandibular movements [53]. Temporomandibular disorder is a collective term embracing several problems that involve the temporomandibular joint, masticatory muscles, or both and treated usually with conservative and reversible therapy. Regular application of the ozone to the TMJ region with special probes developed for deep tissue stimulation allows for access to deep tissue under the skin. Ozone application increases the oxygenation of muscle and cartilage tissue and the creation of anti-inflammatory effect. This can be used as a noninvasive treatment method in patients with TMD. In addition, there are different current treatment modalities reported in the literature, including medication therapy, low-level laser therapy, vibratory stimulation, and, more recently, bio-oxidative ozone therapy which reduced pain in the TMJ region and improved in TMD-induced mouth opening problems after regular treatments [54, 55].

## 7. Role of ozone in endodontics

Ozone is intensively used in root canal therapy due to its strong antimicrobial properties and absence of cytotoxicity. Ozone can be an effective agent when it is used in adequate concentration, time, and applied in a correct way into the root canals after other treatment steps have been performed. Most of the studies on effect of ozone in endodontics investigate its antimicrobial activities in the form of ozone gas, ozonated water, and ozonized oil.

Ozone is a powerful antibacterial agent. In a study, ozone was found to disinfect the bovine tooth dentin tubules effectively [56]. Nagayoshi et al. [27] demonstrated that in concentrations of 0.5–4 mg/L, ozonated water killed pure cultures of *Porphyromonas endodontalis* and *Porphyromonas gingivalis* effectively. These species were found more vulnerable to ozonated water than Gram-positive oral *Streptococci* and *Candida albicans*.

In a study, Hems et al. [57] evaluated antibacterial potential of gas form (produced by Pure zone device) and aqueous (optimal concentration 0.68 mg/L) ozone on the test species

*Enterococcus faecalis*. They found that ozone in solution has antibacterial effect on planktonic *Enterococcus faecalis* after 240 s treatment; however, it shows not much antibacterial effect on *Enterococcus faecalis* within a biofilm.

Estrela et al. [58] studied two forms of ozone—ozonated water and gaseous ozone—with 2.5% hypochlorite and 2% chlorhexidine in infected dental root canals. All agents contacted 20 min and none of them had killed *Enterococcus faecalis* in human-infected root canals.

Use of gas delivery of ozone at a flow rate of 0.5–1 l/min with a net volume of 5 gm/ml for 2–3 min gave favorable result in eliminating pathogen species in the root canal [59].

As an intracanal irrigant, ozonated water can be used in infected necrotic canals, and as intracanal dressing, ozonized oils can be used to reduce target anaerobic biota. Ozone also enhances tissue regeneration and bone healing when used as a canal irrigant. Moreover, ozone water with sonification has antimicrobial effect in comparison to 2.5% NaOCl when used in the disinfection of the root canal [60].

Conflicting reports in term of antimicrobial effect of ozone on endodontic infections were presented in a review [61]. As a result, contradictory results regarding the efficacy of endodontic ozone administration have been reported in the literature.

## 8. Role of ozone in orthodontics

In orthodontic treatments, diffuse opacity of enamel is commonly seen due to the effect of bonding material on enamel surface, as well as white spot lesions have been seen in first 4 weeks of the treatment. White spot lesion formation usually begins at bracket and tooth interface and can reach beneath the bracket area. Hence, prophylactic therapy of enamel has an immense importance in orthodontic treatments.

Ghobashy et al. [62] studied on reducing demineralization of enamel bonded to the orthodontic bracket using ozonized olive oil. Patients who used ozonized olive oil gel with traditional oral hygiene instructions had significantly less decalcification areas during the orthodontic treatment.

Ozone also has a strong oxidizing effect that might cause weak adhesions between tooth and resin due to the negative effect of oxygen inhibition of polymerization. Cehreli et al. [63] evaluated the effect of prophylactic ozone pretreatment of enamel on shear bond strength of orthodontic brackets bonded with total or self-etch adhesive systems. Study revealed that ozone pretreatment of enamel did not have an effect on the shear bond strength of adhesive systems. Shear bond strength values of specimens in ozone group were even slightly higher.

## 9. Role of ozone in pedodontics

Ozone treatment has become more and more popular in the dental clinic every day, and it has become effective in many treatment and application procedures in pedodontics.

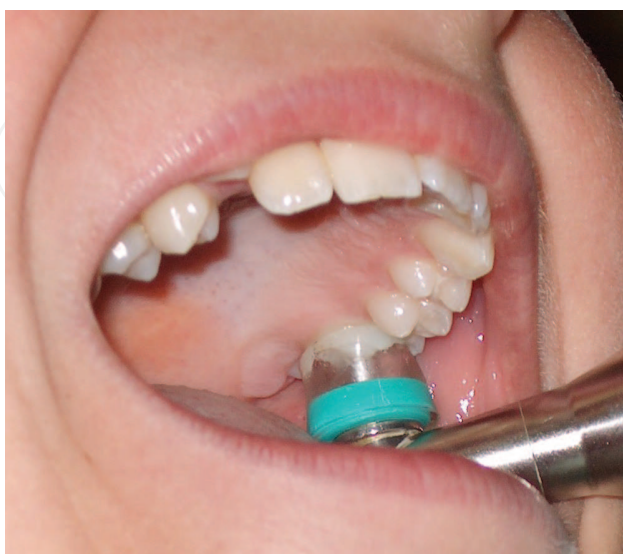Applications of ozone in pediatric dentistry [4].

- a. Application in initial caries (remineralization effect).
- b. Application in root-surface caries (antibacterial effect).
- c. Use as a root channel disinfectant (antibacterial effect).
- d. Accelerate wound healing after surgical treatment.
- e. Treatment of oral ulcers and aphthae.
- f. Treatment of temporomandibular joint dysfunctions and irregularities.
- g. In tooth bleaching applications.

The use of ozone has positive effects on children, especially in terms of cooperation, such as not making noise, having very small hoods, not generating heat or bad smell, water spray or loud sounds of suction, and not needing hand tools [4, 64]. Ozone prevents the caries formation via inhibiting the reproduction of pathogenic microorganisms, or destroying the cell wall by neutralizing or blocking [21, 65, 66] (**Figure 4**).

During this time, ozone attacks glycoproteins, glycolipids, and other amino acids and blocks enzymatic control systems of cells. Thus, the permeability of the cell membrane increases, extending to stop cell viability. After that, the ozone molecules can quickly enter the cell and cause the death of microorganisms [66].

In addition, ozone is an oxidative agent and can provide remineralization of demineralized dentin [21, 65]. The strongest acid naturally produced by acidogenic bacteria during caries formation is pyruvic acid. Pyruvic acid reacts with ozone and decarboxylates oxidatively to acetate and carbon dioxide. The remineralization of the initial caries lesions is supported by the buffered plaque fluid formed by the production of acetate [68]. Theoretically, ozone can be



**Figure 4.** Ozone can be used easily on children [67].

used to reduce the number of bacteria in active caries lesions and consequently can temporarily stop caries progression; caries restoration can be delayed or prevented [22, 69].

In particular, studies have shown that ozone efficacy on pit and fissures where bacterial elimination was very difficult and the most susceptible areas for development of caries [70].

In a randomized clinical trial conducted by Huth et al. [71], 41 children aged 3–7 years were evaluated. A total of 51 patients with pairs of teeth having cavitation-free initial decay were separated into two groups and 40 s ozone (HealOzone-Kavo Dental GmbH Germany) was administered to the study group. After 3 months of clinical observation and DIAGNOdent measurements, regression and remineralization of initial caries were observed in ozone-treated teeth, but the results were not statistically significant.

In dental ozone applications, it is aimed to fix early lesions without altering the anatomical shape of the tooth, thanks to specially developed prophylactic tips. The first patient group to use this technique, which prevents unnecessary hard tissue loss in anterior and posterior initial caries lesions, is children.

A study was conducted with apprehensive children to determine ozone efficacy in open single-surface caries lesions. A total of 82 patients with single-surface caries lesions were separated into two groups and ozone was not applied to the control group, while ozone (HealOzone-Cavo Dental GmbH Germany) was applied to the other group for 20 sec. In ozone-treated group, hardness values improved in comparison to the control group. At the same time, when cooperative evaluation and assessment of dental anxiety was conducted on children, it was stated that ozone application was less worrying in child patients and more acceptable due to short-time application, sound, and water withdrawal [72].

In cavitated lesions, especially ozone gas application provides an antibacterial effect in the cavity surface and satisfies intended to stop progression of the lesion. Although there is not enough clinical experience about the interval and dose of ozone gas to prevent the lesion becoming active after a certain period of cavitated caries lesions, it is thought that promising results can be obtained especially in children who have difficulties in cooperativeness, and this technique may be developed widely and used in routine clinical practice.

## 10. Conclusion

Scientific studies show that ozone can be a promising therapeutic agent in the practice of dentistry. Besides atraumatic application and antimicrobial effects of ozone, carrying toxic risk and can have deadly consequences of wrong actions also incomplete understanding of the mechanism of action many clinicians approach suspicious to ozone. Considering the studies done so far, it can be said that ozone can be used as an additional application besides applications such as antiseptics and local antibiotics, which are given in addition to dental treatments. As a result, more clinical studies on ozone therapy should be performed and well-defined parameters should be established. However, more studies on ozone are required in order to be used routinely in dental treatments.

## Author details

Aysan Lektemur Alpan<sup>1\*</sup> and Olcay Bakar<sup>2</sup>

\*Address all correspondence to: ysnlpn@gmail.com

1 Faculty of Dentistry, Department of Periodontology, Pamukkale University, Denizli, Turkey

2 Faculty of Dentistry, Department of Periodontology, Erzincan University, Erzincan, Turkey

## References

- [1] Bocci V. How ozone acts and how it exerts therapeutic effects. In: Lynch E, editor. *Ozone: The Revolution in Dentistry*. London: Quintessence Publishing Co; 2004. pp. 15-22. ISBN 1-85097-088-2
- [2] Bocci VA. Scientific and medical aspects of ozone therapy. State of the art. *Archives of Medical Research*. 2006;**37**(4):425-435. DOI: 10.1016/j.arcmed.2005.08.006
- [3] Makkar S, Makkar M. Ozone-treating dental infections. *Indian Journal of Stomatology*. 2011;**2**(4):256-259. Available from: <http://indianjournalofstomatology.com/files/dec/11.pdf> [Accessed December 29, 2017]
- [4] Azarpazhooh A, Limeback H. The application of ozone in dentistry: A systematic review of literature. *Journal of Dentistry*. 2008;**36**(2):104-116. DOI: 10.1016/j.jdent.2007.11.008
- [5] Saini R. Ozone therapy in dentistry: A strategic review. *Journal of Natural Science, Biology and Medicine*. 2011;**2**(2):151-153. DOI: 10.4103/0976-9668.92318
- [6] Bhateja S. The miraculous healing therapy; ozone therapy in dentistry. *Indian Journal of Dentistry*. 2012;**3**:150-155. DOI: 10.1016/j.ijd.2012.04.004
- [7] Bocci V. *Ozone: A New Medical Drug*. 2nd ed. Netherlands: Springer Publishing; 2005,2010. pp. 5-234. DOI: 10.1007/978-90-481-9234-2
- [8] Celiberti P, Pazera P, Lussi A. The impact of ozone treatment on enamel physical properties. *American Journal of Dentistry*. 2006;**19**(1):67-72. PMID: 16555661
- [9] Tiwari S, Avinash A, Katiyar S, Iyer A, Jain S. Dental applications of ozone therapy: A review of literature. *The Saudi Journal for Dental Research*. 2017;**8**(1-2):105-111. DOI: 10.1016/j.sjdr.2016.06.005
- [10] Das S. Application of ozone therapy in dentistry. *Indian Journal of Dental Advancements*. 2011;**3**:538-542. ISSN: 2229-5038
- [11] Mosallam RS, Nemat A, El-Hoshy A, Suzuki S. Effect of oleozon on healing of exposed pulp tissues. *Journal of American Science*. 2011;**7**:34-44. ISSN: 1545-1003
- [12] Bocci V. Is it true that ozone is always toxic? The end of a dogma. *Toxicology and Applied Pharmacology*. 2006;**216**(3):493-504. DOI: 10.1016/j.taap.2006.06.009

- [13] Bocci V, Aldinucci C. Biochemical modifications induced in human blood by oxygenation-ozonation. *Journal of Biochemical and Molecular Toxicology*. 2006;**20**(3):133-138. DOI: 10.1002/jbt.20124
- [14] Nogales CG, Ferrari PH, Kantorovich EO, Lage-Marques JL. Ozone therapy in medicine and dentistry. *The Journal of Contemporary Dental Practice*. 2008;**9**(4):75-84. PMID:18473030
- [15] Gupta G, Mansi B. Ozone therapy in periodontics. *Journal of Medicine and Life*. 2012; **5**(1):59-67. PMID: PMC3307081
- [16] Cardoso CC, Carvalho JC, Ovando EC, Macedo SB, Dall'Aglio R, Ferreira LR. Action of ozonized water in preclinical inflammatory models. *Pharmacological Research*. 2000;**42**(1):51-54. DOI: 10.1006/phrs.1999.0646
- [17] Available from: [http://www.wh.com/en\\_global/dental-products/prophylaxis-periodontology/ozonedevices/prozone/](http://www.wh.com/en_global/dental-products/prophylaxis-periodontology/ozonedevices/prozone/) [Accessed: December 30, 2017]
- [18] Baysan A, Whiley RA, Lynch E. Antimicrobial effect of a novel ozone- generating device on micro-organisms associated with primary root carious lesions in vitro. *Caries Research*. 2000;**34**(6):498. DOI: 10.1159/000016630
- [19] Holmes J. Clinical reversal of root caries using ozone, double-blind, randomised, controlled 18-month trial. *Gerodontology*. 2003;**20**(2):106-114. DOI: 10.1111/j.1741-2358.2003.00106.x
- [20] Samuel SR, Dorai S, Khatri SG, Patil ST. Effect of ozone to remineralize initial enamel caries: In situ study. *Clinical Oral Investigations*. 2016 Jun;**20**(5):1109-1113. DOI: 10.1007/s00784-016-1710-x
- [21] Polydorou O, Pelz K, Hahn P. Antibacterial effect of an ozone device and its comparison with two dentin-bonding systems. *European Journal of Oral Sciences*. 2006;**114**(4):349-353. DOI: 10.1111/j.1600-0722.2006.00363.x
- [22] Rickard GD, Richardson R, Johnson T, McColl D, Hooper L. Ozone therapy for the treatment of dental caries. *Cochrane Database of Systematic Reviews*. 2004;**3**:CD004153. DOI: 10.1002/14651858.CD004153.pub2
- [23] Holmes J, Daley T. Sensitivity & Cracked Teeth Treatment With Ozone. 2003. Available from: <http://www.the-o-zone.cc/book/bookch/ch25.html> [Accessed: December 30, 2017]
- [24] Deepa T, Pooja S. Ozone therapy in conservative dentistry and endodontics: An overview. *Indian Journal of Stomatology*. 2012;**3**:165-169
- [25] Tessier J, Rodriguez PN, Lifshitz F, Friedman SM, Lanata EJ. The use of ozone to lighten teeth. An experimental study. *Acta Odontológica Latinoamericana*. 2010;**23**(2):84-89. PMID: 21053679
- [26] Available from: [http://www.wh.com/en\\_global/dental-newsroom/reportsandstudies/new-article/00228/](http://www.wh.com/en_global/dental-newsroom/reportsandstudies/new-article/00228/) [Accessed: December 30, 2017]
- [27] Nagayoshi M, Fukuizumi T, Kitamura C, Yano J, Terashita M, Nishihara T. Efficacy of ozone on survival and permeability of oral microorganisms. *Oral Microbiology and Immunology*. 2004;**19**(4):240-246. DOI: 10.1111/j.1399-302X.2004.00146.x



- [28] Huth KC, Quirling M, Lenzke S, Paschos E, Kamereck K, Brand K, et al. Effectiveness of ozone against periodontal pathogenic microorganisms. *European Journal of Oral Sciences*. 2011;**119**(3):204-210. DOI: 10.1111/j.1600-0722.2011.00825.x
- [29] Ramzy MI, Gomaa HE, Mostafa MI. Management of aggressive periodontitis using ozonized water. *Egypt. Med. J. N R C*. 2005;**6**(1):229-245. Available from: <http://www.the-o-zone.cc/research/abstracts/007.pdf> [Accessed: April 06, 2018]
- [30] Dodwad VGS, Kumar K, Sethi M, Masamatti S. Changing paradigm in pocket therapy- ozone versus conventional irrigation. *Journal of Public Health Dentistry*. 2011;**2**(7):7-12. Available from: <http://journalgateway.com/ijphd/article/view/437/768> [Accessed: December 30, 2017]
- [31] Eltas A, Yavuzer D. Dişeti enflamasyonun tedavisinde gaz ozonun klinik etkilerinin değerlendirilmesi. *İnönü Üniversitesi Sağlık Bilimleri Dergisi*. 2012;**2**:29-33. Article in Turkish
- [32] Yilmaz S, Algan S, Gursoy H, Noyan U, Kuru BE, Kadir T. Evaluation of the clinical and antimicrobial effects of the Er:YAG laser or topical gaseous ozone as adjuncts to initial periodontal therapy. *Photomedicine and Laser Surgery*. 2013;**31**(6):293-298. DOI: 10.1089/pho.2012.3379
- [33] Karapetian VE, Neugebauer J, Clausnitzer CE, Zoller JE. Available from: [http://www.helbo.de/fileadmin/docs/wissenschaft/poster\\_karapetian\\_0304.pdf](http://www.helbo.de/fileadmin/docs/wissenschaft/poster_karapetian_0304.pdf) [Accessed: December 30, 2017]
- [34] Hauser-Gerspach I, Vadaszan J, Deronjic I, Gass C, Meyer J, Dard M, et al. Influence of gaseous ozone in peri-implantitis: Bactericidal efficacy and cellular response. An in vitro study using titanium and zirconia. *Clinical Oral Investigations*. 2012;**16**(4):1049-1059. DOI: 10.1007/s00784-011-0603-2
- [35] Ozdemir H, Toker H, Balci H, Ozer H. Effect of ozone therapy on autogenous bone graft healing in calvarial defects: A histologic and histometric study in rats. *Journal of Periodontal Research*. 2013;**48**(6):722-726. DOI: 10.1111/jre.12060
- [36] Kazancioglu HO, Ezirganli S, Aydin MS. Effects of laser and ozone therapies on bone healing in the calvarial defects. *The Journal of Craniofacial Surgery*. 2013;**24**(6):2141-2146. DOI: 10.1097/SCS.0b013e3182a244ae
- [37] Kan B, Sencimen M, Bayar GR, Korkusuz P, Coskun AT, Korkmaz A, et al. Histomorphometric and microtomographic evaluation of the effects of hyperbaric oxygen and systemic ozone, used alone and in combination, on calvarial defect healing in rats. *Journal of Oral and Maxillofacial Surgery*. 2015;**73**(6):1231. DOI: 10.1016/j.joms.2015.02.018
- [38] Alpan AL, Toker H, Ozer H. Ozone therapy enhances osseous healing in rats with diabetes with calvarial defects: A morphometric and immunohistochemical study. *Journal of Periodontology*. 2016;**87**(8):982-989. DOI: 10.1902/jop.2016.160009
- [39] Stubinger S, Sader R, Filippi A. The use of ozone in dentistry and maxillofacial surgery: A review. *Quintessence International*. 2006;**37**(5):353-359. PMID: 16683682

- [40] Kazancioglu HO, Kurklu E, Ezirganli S. Effects of ozone therapy on pain, swelling, and trismus following third molar surgery. *International Journal of Oral and Maxillofacial Surgery*. 2014;**43**(5):644-648. DOI: 10.1016/j.ijom.2013.11.006
- [41] Ahmedi J, Ahmedi E, Sejfiya O, Agani Z, Hamiti V. Efficiency of gaseous ozone in reducing the development of dry socket following surgical third molar extraction. *European Journal of Dentistry*. 2016;**10**(3):381-385. DOI: 10.4103/1305-7456.184168
- [42] Yucesoy T, Kutuk N, Canpolat DG, Alkan A. Comparison of ozone and photo-biomodulation therapies on mental nerve injury in rats. *Journal of Oral and Maxillofacial Surgery*. 2017;**75**(11):2323-2332. DOI: 10.1016/j.joms.2017.04.016
- [43] Vescovi P, Nammour S. Bisphosphonate-related osteonecrosis of the jaw (BRONJ) therapy. A critical review. *Minerva Stomatologica*. 2010;**59**(4):181-203; 204-213. PMID: 20360666
- [44] Agapov VS, Shulakov VV, Fomchenkov NA. Ozone therapy of chronic mandibular osteomyelitis. *Stomatologiia (Mosk)*. 2001;**80**(5):14-17. PMID: 11696944
- [45] Agrillo A, Petrucci MT, Tedaldi M, Mustazza MC, Marino SM, Gallucci C, et al. New therapeutic protocol in the treatment of avascular necrosis of the jaws. *The Journal of Craniofacial Surgery*. 2006;**17**(6):1080-1083. DOI: 10.1097/01.scs.0000249350.59096.d0
- [46] Agrillo A, Ungari C, Filiaci F, Priore P, Iannetti G. Ozone therapy in the treatment of avascular bisphosphonate-related jaw osteonecrosis. *The Journal of Craniofacial Surgery*. 2007;**18**(5):1071-1075. DOI: 10.1097/scs.0b013e31857261f
- [47] Batinjan G, Filipovic Zore I, Vuletic M, Rupic I. The use of ozone in the prevention of osteoradionecrosis of the jaw. *Saudi Medical Journal*. 2014;**35**(10):1260-1263. PMID: PMC4362119
- [48] Akdeniz SS, Beyler E, Korkmaz Y, Yurtcu E, Ates U, Araz K, et al. The effects of ozone application on genotoxic damage and wound healing in bisphosphonate-applied human gingival fibroblast cells. *Clinical Oral Investigations*. 2017:11. DOI: 10.1007/s00784-017-2163-6
- [49] Dogan R, Hafiz AM, Kiziltan HS, Yenigun A, Buyukpinarbaslili N, Eris AH, et al. Effectiveness of radiotherapy+ozone on tumoral tissue and survival in tongue cancer rat model. *Auris, Nasus, Larynx*. 2017;**45**:5. DOI: 10.1016/j.anl.2017.03.017
- [50] Arita M, Nagayoshi M, Fukuizumi T, Okinaga T, Masumi S, Morikawa M, et al. Microbicidal efficacy of ozonated water against *Candida albicans* adhering to acrylic denture plates. *Oral Microbiology and Immunology*. 2005;**20**(4):206-210. DOI: 10.1111/j.1399-302X.2005.00213.x
- [51] Oizumi M, Suzuki T, Uchida M, Furuya J, Okamoto Y. In vitro testing of a denture cleaning method using ozone. *Journal of Medical and Dental Sciences*. 1998;**45**(2):135-139. PMID:11186199
- [52] Kumar T, Arora N, Puri G, Aravinda K, Dixit A, Jatti D. Efficacy of ozonized olive oil in the management of oral lesions and conditions: A clinical trial. *Contemporary Clinical Dentistry*. 2016;**7**(1):51-54. DOI: 10.4103/0976-237X.177097

- [53] Howard JA. Temporomandibular joint disorders in children. *Dental Clinics of North America*. 2013;**57**(1):99-127. DOI: 10.1016/j.cden.2012.10.001
- [54] Celakil T, Muric A, Gokcen Roehlig B, Evlioglu G, Keskin H. Effect of high-frequency bio-oxidative ozone therapy for masticatory muscle pain: A double-blind randomised clinical trial. *Journal of Oral Rehabilitation*. 2017;**44**(6):442-451. DOI: 10.1111/joor.12506
- [55] Celakil T, Muric A, Gokcen Roehlig B, Evlioglu G. Management of pain in TMD patients: Bio-oxidative ozone therapy versus occlusal splints. *Cranio. The Journal of Craniomandibular & Sleep Practice*. 2017:1-9. ISSN: 0886-9634 (Print) 2151-0903 (Online) Journal homepage: <http://www.tandfonline.com/loi/ycra20> doi:10.1080/08869634.2017.1389506
- [56] Nagayoshi M, Kitamura C, Fukuizumi T, Nishihara T, Terashita M. Antimicrobial effect of ozonated water on bacteria invading dentinal tubules. *Journal of Endodontia*. 2004;**30**(11):778-781. PMID: 15505509
- [57] Hems RS, Gulabivala K, Ng YL, Ready D, Spratt DA. An in vitro evaluation of the ability of ozone to kill a strain of *Enterococcus faecalis*. *International Endodontic Journal*. 2005;**38**(1):22-29. DOI: 10.1111/j.1365-2591.2004.00891.x
- [58] Estrela C, Estrela CR, Decurcio DA, Hollanda AC, Silva JA. Antimicrobial efficacy of ozonated water, gaseous ozone, sodium hypochlorite and chlorhexidine in infected human root canals. *International Endodontic Journal*. 2007;**40**(2):85-93. DOI: 10.1111/j.1365-2591.2006.01185.x
- [59] Siqueira JF Jr, Rôças IN, Cardoso CC, Macedo SB, Lopes HP. Antibacterial effects of a new medicament—the ozonized oil—compared to calcium hydroxide pastes (original article in Portuguese). *Revista Brasileira de Odontologia*. 2000;**57**:252-256
- [60] Reddy SARN, Dinapadu S, Reddy M, Pasari S. Role of ozone therapy in minimal intervention dentistry and endodontics—A review. *Journal of International Oral Health*. 2013;**5**(3):102-108. PMID: PMC3769872
- [61] Good M, El KI, Hussey DL. Endodontic 'solutions.' Part 1: A literature review on the use of endodontic lubricants, irrigants and medicaments. *Dental Update*. 2012;**39**(4):239-240; 42-44, 46. PMID: 22774686
- [62] Ghobashy SA, El-Tokhey HM. In vivo study of the effectiveness of ozonized olive oil gel on inhibiting enamel demineralization during orthodontic treatment. *Journal of American Science*. 2012;**8**(10):657-666. Available from: <http://www.jofamericanscience.org/journals/am-sci/am0810/>. [Accessed: December 30, 2017]
- [63] Cehreli SB, Guzey A, Arhun N, Cetinsahin A, Unver B. The effects of prophylactic ozone pretreatment of enamel on shear bond strength of orthodontic brackets bonded with total or self-etch adhesive systems. *European Journal of Dentistry*. 2010;**4**(4):367-373. PMID: PMC2948738

- [64] Grootveld M, Baysan A, Sidiiquei N, Sim J, Silwood C, Lynch E. History of clinical applications of ozone. In: Lynch E, editor. *Ozone: The Revolution in Dentistry*. London: Quintessence Publishing; 2004. pp. 23-30
- [65] Bezirtzoglou E, Cretoiu SM, Moldoveanu M, Alexopoulos A, Lazar V, Nakou M. A quantitative approach to the effectiveness of ozone against microbiota organisms colonizing toothbrushes. *Journal of Dentistry*. 2008;**36**(8):600-605. DOI: 10.1016/j.jdent.2008.04.007
- [66] Baysan A, Lynch E. Clinical reversal of root caries using ozone: 6-month results. *American Journal of Dentistry*. 2007;**20**(4):203-208. PMID: 17907479
- [67] Gojanur S. Ozone Therapy – An Alternative to Conventional Therapy in Pediatric Dentistry. 2016. Available from: <http://www.dentalnewsweek.com/?p=991> [Accessed: December 30, 2017]
- [68] Margolis HC, Moreno EC, Murphy BJ. Importance of high pKA acids in cariogenic potential of plaque. *Journal of Dental Research*. 1985;**64**(5):786-792. DOI: 10.1177/00220345850640050101
- [69] Jayarajan J, Janardhanam P, Jayakumar P. Efficacy of CPP-ACP and CPP-ACPF on enamel remineralization—An in vitro study using scanning electron microscope and DIAGNOdent. *Indian Journal of Dental Research*. 2011;**22**(1):77-82. DOI: 10.4103/0970-9290.80001
- [70] Brazzelli M, McKenzie L, Fielding S, Fraser C, Clarkson J, Kilonzo M, et al. Systematic review of the effectiveness and cost-effectiveness of HealOzone for the treatment of occlusal pit/fissure caries and root caries. *Health Technology Assessment*. 2006;**10**(16):1-6 PMID: 16707073
- [71] Huth KC, Paschos E, Brand K, Hickel R. Effect of ozone on non-cavitated fissure carious lesions in permanent molars. A controlled prospective clinical study. *American Journal of Dentistry*. 2005;**18**(4):223-228. PMID: 16296426
- [72] Dahnhardt JE, Jaeggi T, Lussi A. Treating open carious lesions in anxious children with ozone. A prospective controlled clinical study. *American Journal of Dentistry*. 2006;**19**(5):267-270. PMID: 17073201

