

# A RARE CASE REPORT OF HYPERREACTIO LUTEINALIS – AN OVAR(Y) REACTIVENESS UPSHOT

Dr.K.Manimekalai,  
Associate Professor & Head,  
Department of Computer Applications,  
Sri GVG Visalakshi College for Women,  
Udumalpet - 642 128.

Dr.K.Indhuja Abirami  
Post Graduate in OBSTETRICS and  
GYNAECOLOGY,  
Department of Obstetrics and Gynaecology  
Government Thiruvavarur Medical College,  
Thiruvavarur.

## Abstract

Hyperreactio luteinalis is a rare condition in pregnancy that is caused by high  $\beta$ -human chorionic gonadotropin levels. It is mostly seen in patients with trophoblastic diseases, multiple pregnancies or after infertility treatment or in third trimester. The aim of this study is to enlighten the significance of knowing Hyperreactio luteinalis, the benign, self-limiting ovarian pathology which does not need any specific treatment except in cases of surgical emergencies like ovarian torsion. It also necessitates differentiation from other malignant mimics.

Keywords: *Hyperreactio luteinalis, Theca Lutein Cyst,  $\beta$ -human chorionic gonadotropin, ovarian torsion.*

## I. INTRODUCTION

Hyperreactio luteinalis is a rare condition caused by increased levels of serum  $\beta$ hCG after first trimester or may be due to abnormal sensitivity of the hCG receptor due to gene mutation leading to luteinization of follicular theca interna layer.

It occurs during pregnancy and is characterized by the presence of abnormally large ovarian cysts known as luteinized cysts. These cysts develop from the corpus luteum, a structure that forms in the ovary after ovulation.

Normally, the corpus luteum produces hormones such as progesterone to support early pregnancy. In hyperreactio luteinalis, there is an exaggerated response of the ovaries to the hormonal changes associated with pregnancy, leading to the development of unusually large cysts.

1. Size of Cysts: The cysts associated with hyperreactio luteinalis can be significantly larger than typical functional ovarian cysts. They may reach sizes of several centimeters.
2. Bilateral Involvement : Unlike regular ovarian cysts, hyperreactio luteinalis often involves both ovaries.

3. Association with Pregnancy : This condition is typically seen in pregnant women, especially those with multiple gestations (twins, triplets, etc.). It is thought to be related to the higher levels of hormones produced during multiple pregnancies.
4. Benign Nature : Hyperreactio luteinalis is generally a benign condition and does not require specific treatment. The cysts usually regree on their own after delivery or resolution of the pregnancy.
5. Symptoms : Women with hyperreactio luteinalis may not have specific symptoms, but in some cases, they may experience abdominal pain or discomfort.
6. Diagnosis : Diagnosis is often made through imaging studies such as ultrasound, which can reveal the presence of large ovarian cysts. Blood tests may also show elevated levels of hormones associated with the corpus luteum.

## II. CASE PRESENTATION

A 28 year-old Primigravida at 18 weeks of gestation, spontaneously conceived, came with acute abdomen associated with vomitting. Patient vitals were stable. On transabdominal ultrasonogram, bilateral multicystic ovaries with spoke wheel pattern was seen with Right ovary enlarged to 12 x 7 cm with features of torsion. Colour Doppler velocimetry showed sluggish blood flow .Left ovary enlarged to 9.9 x 9cm, both containing more than 10 thin walled locules with clear fluid and no soild components. Serum  $\beta$ hCG was 79,345 mIU/ml. Other blood analysis were normal. Fetus was appropriate to gestational age with no gross anomalies.

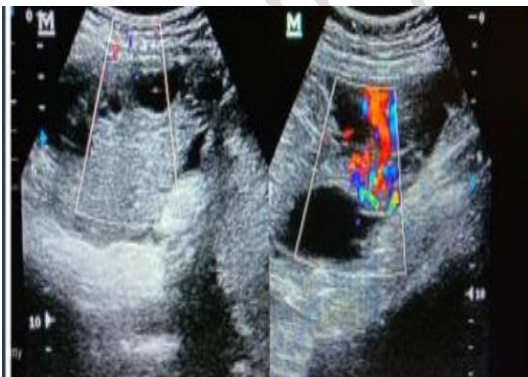

Fig 1- Colour velocimetry showing absent blood flow in right ovary

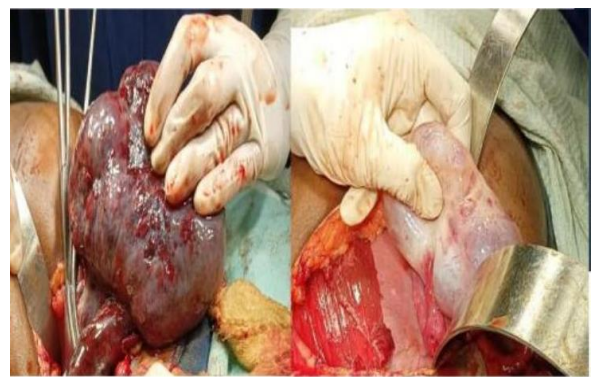


Fig 2 -Right ovarian torsion with gangrenous stroma

Left ovary -enlarged with theva lutein cysts

## Management

Emergency laparotomy with Right adnexectomy done in view of Right Ovarian torsion with failed attempts of detorsion.

### **Pregnancy Outcome**

Patient had spontaneous vaginal delivery of 3.8kg boy at 39 weeks

### **III. DISCUSSION**

The condition is usually benign but needs intervention in case of surgical intervention like torsion. We must be able to differentiate from OHSS and ovarian tumors which can lead to unnecessary surgeries.

### **IV. CONCLUSION**

Most often, they does not need any intervention/medications. Based on the size of these multicystic ovaries, the patients may have pain or may undergo torsion, cyst rupture, or pelvic entrapment of enlarged ovary, which then becomes a surgical emergency. These patients may develop hyperandrogenism due to elevated  $\beta$  hCG levels and require appropriate management. The size of the cysts subsequently regressed to normal in 3 months postpartum.

### **REFERENCES**

1. Caspi E, Schreyer P, Bukovsky J. Ovarian lutein cysts in pregnancy. *Obstet Gynaecol* 1973;42(3):388-98.
2. Abu-Louz SK, Ahmed AA, Swan RW. Spontaneous ovarian hyperstimulation syndrome with pregnancy. *Am J Obstet Gynaecol* 1997;177(2):476-7.
3. Wajda KJ, Lucas JG, Marsh WL. Hyperreactio luteinalis: benign disorder masquerading as an ovarian neoplasm. *Arch Pathol Lab Med* 1989;113(8):921-5.